

China Scholarship Council – University Maastricht

PhD Programme Application form

Basic information

1. Information on prospective UM supervisors and Promotor

1a. First Supervisor:

- Title(s), initial(s), first name, surname: Dr. J.P.J.M Jill Hikspoors
- Research group: NUTRIM
- Address for correspondence: Universiteitssingel 50
6229ER Maastricht
- Telephone: +31(0)43 388 1189
- E-mail: jill.hikspoors@maastrichtuniversity.nl

1b. Second Supervisor:

- Title(s), initial(s), first name, surname: Prof. Dr. W.H. Wouter Lamers
- Research group: Emeritus
- Address for correspondence: Universiteitssingel 50
6229ER Maastricht
- Telephone: +31(0)43 388 1060
- E-mail: wh.lamers@maastrichtuniversity.nl

1c. Promotor:

- Title(s), initial(s), first name, surname: Prof. Dr. S. Eleonore Koehler
- Research group: NUTRIM/SHE
- Address for correspondence: Universiteitssingel 50
6229ER Maastricht
- Telephone: +31(0)43 388 1191
- E-mail: leo.koehler@maastrichtuniversity.nl

2. Information on UM Faculty/ Department/ Institute/ School contact person:

- Initial(s), first name, surname: Dr. J.P.J.M Jill Hikspoors
- Research group: NUTRIM
- Address for correspondence: Universiteitssingel 50
6229ER Maastricht
- Telephone: +31(0)43 388 1189
- E-mail: jill.hikspoors@maastrichtuniversity.nl

1. Information on the applicant

- Initial(s), first name, surname:
- Male/female:
- Current work address:

- Telephone:
- E-mail:
- WeChat:
- Private address:

2. Details of applicant's home university

Note! A separate letter of recommendation by the supervisor or faculty dean of the home university is required.

- Name of home university:
- Address:
- Telephone:
- E-mail:
- Website (if available):

3. Applicant's home university Master Thesis supervisor:

- Title(s), initial(s), first name, surname:
- Address for correspondence:

- Telephone:
- E-mail:
- WeChat:

4. Research field(s)

Basic research / Biological Foundations of Human Health and Diseases

Keywords: human fetal heart, cardiac valves, 3D-reconstruction, lung veins, conduction system

5. Title of research plan for CSC-UM PhD Programme

The developmental anatomy of the human fetal heart

6. Short summary of research plan (max. 250 words) (A full plan has to be submitted later)

The prenatal heart, including that of humans, is one of the best studied organs. A main reason is probably the prevalence of cardiac malformations, which affect ~1% of newborn children. With ultrasound imaging becoming more and more detailed, an increasing fraction of these cardiac malformations becomes diagnosed prenatally, usually between 12 and 24 weeks of gestation. During this time interval, the details of cardiac structures and function that can be imaged increases strongly. A major drawback that impedes ultrasound imaging of early hearts is that only very few studies have visualized human fetal hearts at cellular detail. We have recently published a pictorial account of human heart development during the first 8 weeks of development (Hikspoors et al., 2022). This account studied heart development at cellular detail, reconstructed 70 structures three-dimensionally, and presented the results as interactive 3D-PDFs. These 3D-PDFs can be interrogated per structure and per developmental stage at a self-chosen viewing angle (Figure 1).

In the present proposal, we aim to prepare a similar inclusive pictorial account of the fetal heart. Such a reference will facilitate the interpretation of the by necessity less detailed ultrasound images. We will make use of serial sections of routinely and immunohistochemically stained sections to prepare the reconstructions. Figure 2 shows a provisional reconstruction of an immunohistochemically stained 33-weeks-old fetal heart. Virtually all structures have formed in the fetal heart, but the relative size of many structures still changes considerably. Specific questions with respect to remodeling that we will address are:

- The transition of both large atrial auricles into relatively small atrial appendages, and the incorporation of the proximal lung veins into the left atrium.
- The growth of the cardiac conduction system, in particular the formation of the atrioventricular node and bundle of His.
- The size and position of the membranous septum
- The shaping of the leaflets and papillary muscles of the cardiac valves.
- Myocardial persistence along the distal coronary sinus, the lung veins, and the subepicardial wall of the arterial valves.

Requirements:

Highly motivated and proactive student with great interest in embryology. Having affection for 3D-modeling is a plus.

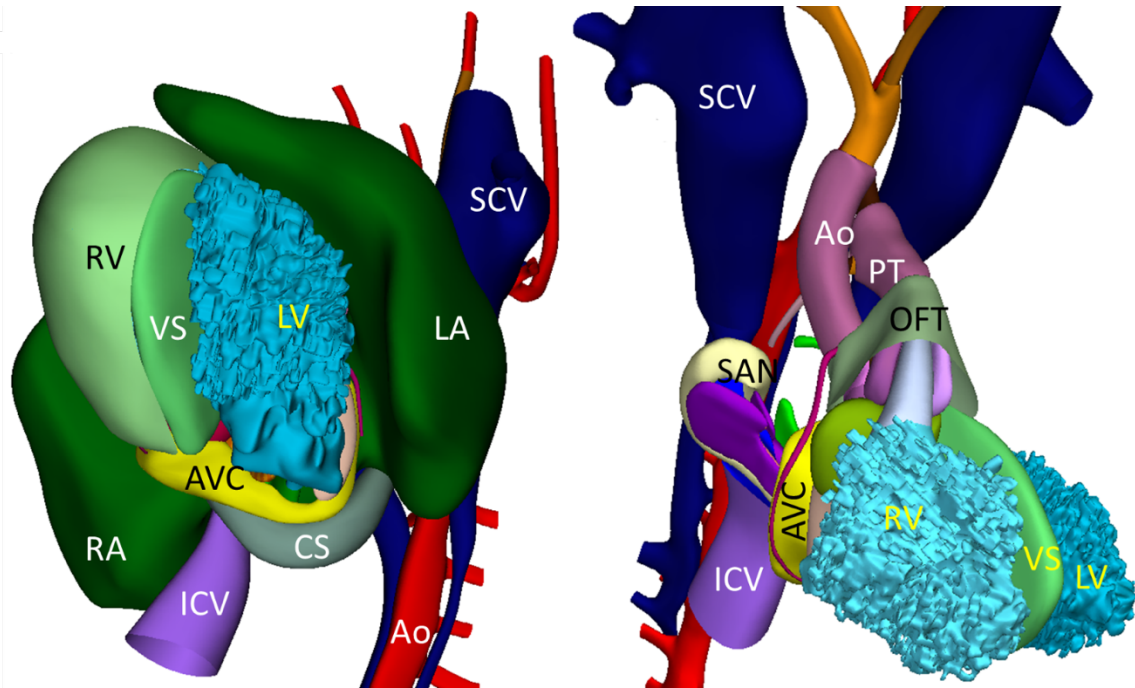


Figure 1. Ventral left and right views of the same 7-weeks old human heart. Left: the wall of the left ventricle is removed, exposing the ventricular trabeculae. Right: the walls of both left and right ventricles are removed. Abbreviations: Ao: aorta; AVC: atrioventricular canal; CS: coronary sinus; ICV: inf caval vein; LA: left atrium; LV: left ventricle; OFT: outflow tract; PT: pulmonary trunk; RA: right atrium; RV: right ventricle; SAN: sinuatrial node; SCV: sup caval vein; VS: ventricular septum.

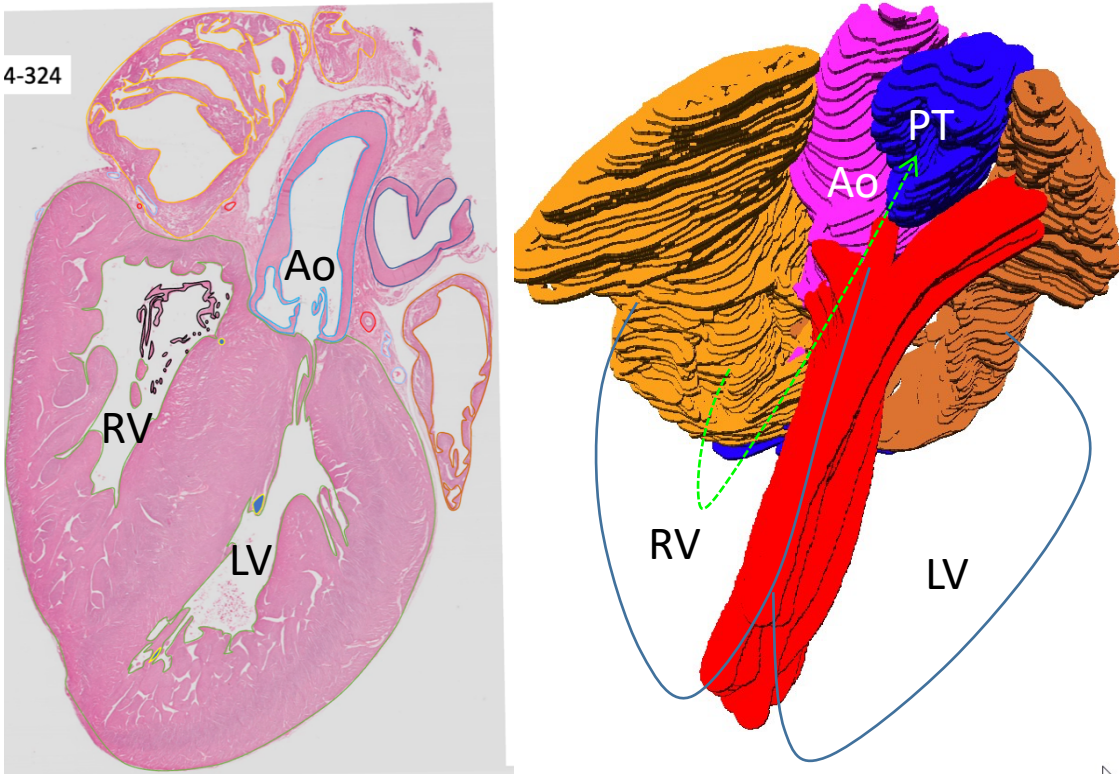


Figure 2. Histological and ventral left views of a 33-week old human heart. Left: segmentation of structures of interest on digital 2D-histological sections in order to build a 3D-model as visualized in the right draft. Right: The ventricles are solely aligned by a line, exposing the blood flow (green arrow) from right atrium to right ventricle followed by its outflow into the pulmonary trunk. Abbreviations: Ao: aorta; RV: right ventricle; LV: left ventricle; PT: pulmonary trunk.

Group's performance:

Jill P.J.M. Hikspoors: Thesis *cum laude*; publications 21; citations 251, H-index 10

Wouter H. Lamers: publications: 449, citations:17048; H-index 69

Selected publications:

J.P.J.M. Hikspoors, N. Kruepunga, G.M.C. Mommen, S.E. Köhler, R.H. Anderson, W.H. Lamers (2022) A pictorial account of the human embryonic heart between 3.5 and 8 weeks of development. *Commun Biol* 5(1): 226 <https://doi.org/10.1038/s42003-022-03153-x>

J.P.J.M. Hikspoors, Y. Macias, J.T. Tretter, R.H. Anderson, W.H. Lamers, T.J. Mohun, D. Sanchez-Quintana, J. Farre, E. Sternick (2022) Miniseries 1—Part I: the Development of the atrioventricular conduction axis. *Europace* 24(3) Pages 432-442 <https://doi.org/10.1093/europace/euab287>

7. Motivation for CSC-UM PhD application (max. 250 words)

Two letters are required, one from the student and one from the promotion team.

Our department has generated a large database with digitized sections of human embryos and fetuses, and has implemented state-of-the-art reconstruction techniques. We have further developed a unique expertise to identify regions of differential growth in development. This CSC-UM grant allows the PhD candidate to use this database to generate a thus far unavailable interactive topographic atlas of fetal heart anatomy.

With our earlier experience of four Chinese graduate students, we are confident that we can successfully generate novel heart models in order to facilitate correct interpretation of the less detailed ultrasound images.

Applicant's Curriculum Vitae (if available)

8. Personal details

Applicant

- Title(s), initial(s), first name, surname:

CSC-UM PhD programme start 1-9-2023

- Surname:

- Nationality: Chinese

- Date of Birth:

- Country and place of birth:

9. Master's degree (if applicable)

Note! Add a copy of your Master's degree to your application

University:

Faculty/discipline:

City and country:

Date:

Grade average:

Title Master's thesis (if applicable):

Thesis grade: